

# *Modified Rhytidectomy that Produces a More Natural Look: Experience with 110 Cases*

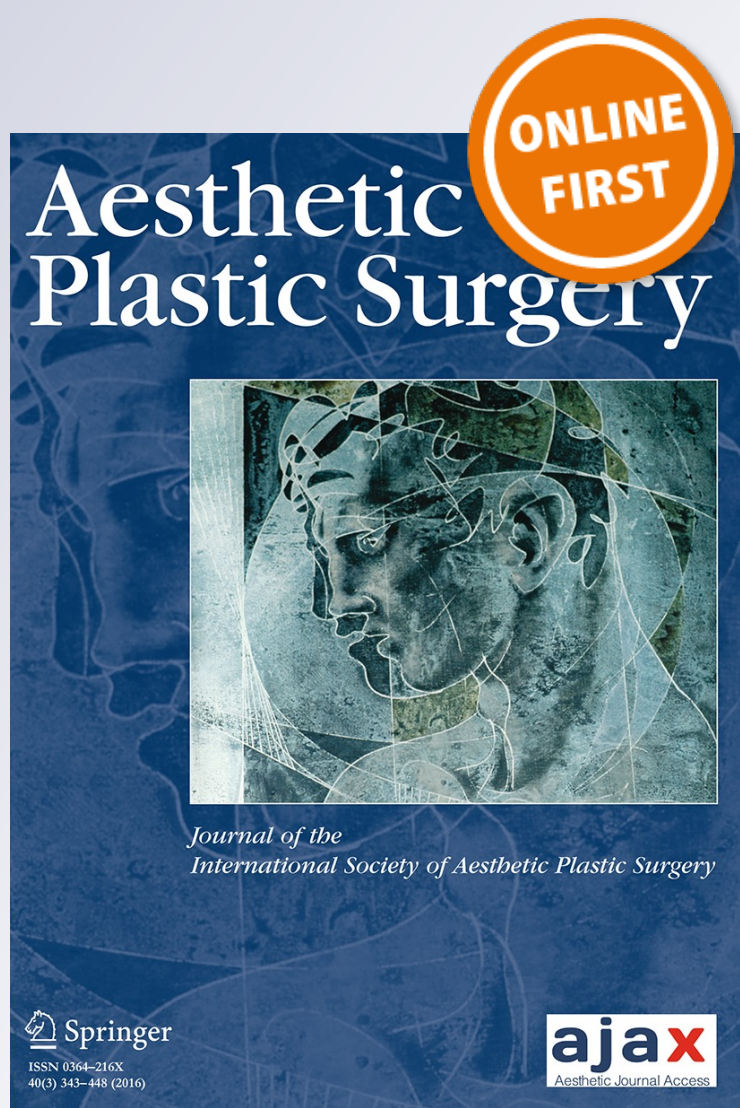**Daniel Man**

**Aesthetic Plastic Surgery**

ISSN 0364-216X

Aesth Plast Surg

DOI 10.1007/s00266-016-0670-5



**Your article is protected by copyright and all rights are held exclusively by Springer Science+Business Media New York and International Society of Aesthetic Plastic Surgery. This e-offprint is for personal use only and shall not be self-archived in electronic repositories. If you wish to self-archive your article, please use the accepted manuscript version for posting on your own website. You may further deposit the accepted manuscript version in any repository, provided it is only made publicly available 12 months after official publication or later and provided acknowledgement is given to the original source of publication and a link is inserted to the published article on Springer's website. The link must be accompanied by the following text: "The final publication is available at [link.springer.com](http://link.springer.com)".**

# Modified Rhytidectomy that Produces a More Natural Look: Experience with 110 Cases

Daniel Man<sup>1</sup>



Received: 28 November 2015 / Accepted: 6 June 2016

© Springer Science+Business Media New York and International Society of Aesthetic Plastic Surgery 2016

## Abstract

**Background** Recognition of the effects of aging on the ear and the mechanisms leading to ear deformity associated with facelift procedures aid in achieving improved aesthetic results. In 2009, the author developed a novel rhytidectomy technique to provide more natural-looking results than those achieved through other facelift procedures, which often result in facial and ear distortion/deformity. This technique is designed to optimize aesthetic outcomes by employing incisions hidden within the ear, autologous fat transfer to restore normally lost facial volume, and absorbable bidirectional sutures, all of which allow less skin removal and shorter, more concealable scars within the inside perimeter of the ear, and thus less-distorted facial contours. In this retrospective study, the author added one important modification to this previously described approach for preventing ear deformity.

**Objectives** The author will show that this modified rhytidectomy technique has many benefits over a traditional rhytidectomy, and it results in a natural-looking facelift.

**Methods** The author modified the original technique to secure the ears in a way that prevents inferior drifting. The modified technique involves the placement of two parallel strands of 3-0 Monocryl sutures

under the scalp and over the skull and running from one side of the head to the other side using a 6-inch blunt needle. The absorbable strands are passed from the inferior part of each earlobe—one in front of the ear and the other in back of the ear. The strands are tied with knots under moderate tension under each earlobe, securing the ear back in the anatomical preoperative position. This secures the bottom of the ears and prevents caudal drifting.

**Discussion** The use of 360° round-block, inside-the-ear incisions is advantageous. These incisions have much less lymphatic derangement of the skin, because the overall cut is shorter and the skin is not cut as extensively as in other methods that use longer incisions to get rid of more excess skin in facelifts.

**Results** This modified rhytidectomy technique has many benefits over a traditional rhytidectomy: the incisions are hidden inside the ears, so there are almost no visible external incisions, and there is no deformity of the ears and earlobes, because the ears do not drift downward. The ear canal is not distorted, there is no hairline distortion, and most importantly, it results in a natural-looking facelift without the commonly seen deformity of any noticeable pulling.

**Conclusions** This modified approach to rhytidectomy achieves natural looking, aesthetically pleasing results.

**Level of Evidence III** This journal requires that authors assign a level of evidence to each article. For a full description of these Evidence-Based Medicine ratings, please refer to the Table of Contents or the online Instructions to Authors [www.springer.com/00266](http://www.springer.com/00266).

Dr. Man is a board-certified plastic surgeon in private practice in Boca Raton, Florida.

✉ Daniel Man  
[drdanielman@gmail.com](mailto:drdanielman@gmail.com)

<sup>1</sup> 851 Meadows Road, Suite 222, Boca Raton, FL 33486, USA

**Keywords** Blepharoplasty · Endoscopy · Facelift · Lymphatic derangement · Rhytidectomy · Superficial musculoaponeurotic system

## Introduction

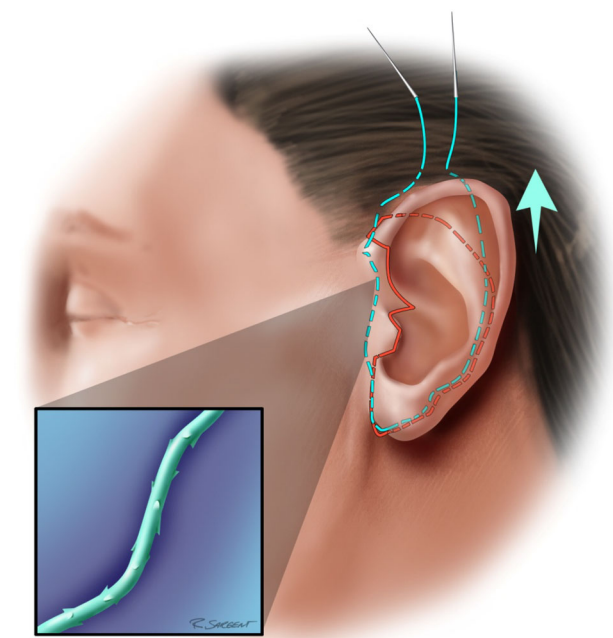
Recognition of the effects of aging on the ear and the mechanisms leading to ear deformity associated with facelift procedures can aid in achieving improved aesthetic results [1]. In 2009, the author developed a novel rhytidectomy technique to provide more natural-looking results than those achieved through other facelift procedures, which often result in facial and ear distortion/deformity (e.g., “lateral sweep,” “Joker’s line,” “pixie ear”) [1]. These distortions arise primarily from traction forces caused by techniques utilized to repair the superficial muscular aponeurotic system (SMAS), neck, and hairline [1]. This technique is designed to optimize aesthetic outcomes by employing incisions hidden within the ear, autologous fat transfer to restore normally lost facial volume, and absorbable bidirectional sutures, all of which allow less skin removal and shorter, more concealable scars within the inside perimeter of the ear, resulting in less-distorted facial contours [1]. The author utilized this modified rhytidectomy surgical technique for procedures that he conducted between 2005 and 2007 [1]. Since then, he has performed more than 500 rhytidectomies with one important modification to this previously described approach for preventing ear deformity.

## Methods

### The Modification to the Original Ear Elevation Technique

In the previous technique introduced in 2009 [1, 9], incisions were made at 360 degrees into and inside the ears, and along the front and back of the ears where they join the facial skin. Loose facial mass tissue was repaired with imbrication, and the ears were raised superiorly using 2-0 absorbable barbed sutures containing small anchors (2-0 Quill sutures, Angiotech Pharmaceuticals; Vancouver, British Columbia, Canada) (Fig. 1) [1]. However, securing the earlobes in a higher position through this method did not always work well, and drifting of the earlobes sometimes reoccurred.

Therefore, the technique was altered so that the ears are secured in a way that prevents inferior caudal drifting. The modified technique involves the placement of two parallel strands of 3-0 Monocryl sutures (Ethicon, Somerville, NJ, USA) passed under the scalp and over the skull and running from one side of the head to the other side using a 6-inch blunt needle. The absorbable strands are passed from the inferior part of each earlobe—one in front of the ear and the other in the back of the ear. The strands are tied

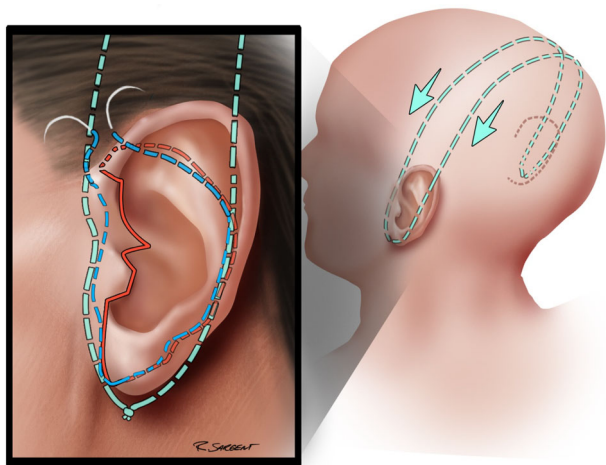


**Fig. 1** U-shaped sutures were utilized to elevate the ear. The red line illustrates round-block incisions that were hidden in the ear. *Inset* Close-up view of the U-shaped bidirectional absorbable barbed suture (light blue) and hidden incisions (red). Man, copyright © 2009 by The American Society for Aesthetic Plastic Surgery, Inc. Reprinted by permission of SAGE Publications [1]. Permission was obtained from the illustrator, Mr. Rick Sargent

with knots under moderate tension under each earlobe, securing the ear back in the anatomical preoperative position (Fig. 2).

In stabilizing the ears, the Monocryl sutures over the skull and under the scalp secure the bottom of the ears and prevent elongation and caudal drifting, thereby achieving long-term aesthetically pleasing results. Once the flaps in front of the ear, back of the ear, and neck are elevated, future face and ear deformities are prevented. Two regular-length 3-0 Monocryl sutures are looped into one another in the middle, forming a longer and stronger double strand. Starting at the bottom of one earlobe at the 6 o'clock position, the surgeon passes one strand with a long-curved Keith needle under the soft tissue posteriorly, hugging the incision until the strand exits at the 12 o'clock position above the ear. The second strand is passed similarly in front of the ear at 6 o'clock, meeting its second strand at the 12 o'clock position above the ear. Using a blunt needle similar in shape to a Reverdin needle, the surgeon passes two strands under the scalp from the 12 o'clock position toward the temple through a small opening. The needle is then passed from one temple to the remaining other temple, pulling these two strands up and over the occiput. Then the strands are passed in a similar fashion to the 12 o'clock position of the remaining other ear. Each strand is





**Fig. 2** Both ears are prevented from drifting caudally through the placement of two parallel strands of 3-0 Monocryl sutures under the scalp and running from one side of the head to the other side using a 6-inch blunt needle. The absorbable strands are passed from the inferior part of each earlobe, one in front of the ear and the other in the back of the ear. The strands are tied with knots under moderate tension under each earlobe, securing the ear in its anatomical preoperative position. *Inset* Close-up view of the U-shaped bidirectional absorbable barbed suture (dark blue) and hidden incisions (red). Permission was obtained from the illustrator, Mr. Rick Sargent

individually passed, one in front of the ear and one in the back of the ear to exit together at the 6 o'clock position of the second ear. The two opposing strands are quickly and strongly pulled, and with moderate tension, four knots are placed at the 6 o'clock position of each earlobe. By doing so, the ears and earlobes have been prevented from drifting caudally, so there is no chance of creating a pulled look. The SMAS and the neck repair work have been completed, and preparation for skin closure is under way.

All facelift procedures conducted in this study were performed in a similar manner since 2010 when the improved technique was introduced, with the two sutures tied deep at the bottom of the earlobe in a knot similar to the enclosed drawing (Fig. 2). Other ancillary procedures, such as forehead endoscopy and upper and lower eyelid blepharoplasty, were performed at the same time, with SMAS plication used in all facelifts as well as platysma muscle suturing into a corset for neck repair as performed by Feldman [2–4].

When combined with the facelift, the earlobe suture technique secures the position and shape of the ears and makes patients look better and feel better about their appearance. These techniques should be performed together to enhance the patient's self-perception. Because the resulting incisions are not noticeable, the technique introduced in this study is especially suitable for bald or thin-haired individuals. The earlobe suture technique is especially important for patients who would like to have fewer visible incisions and do not want to show scars

after having a facelift, and those who wish to have minimal distortions to their appearances, especially where the incision is outside the ears and into the hairlines. However, this technique has shortcomings in patients who have had massive weight loss and in patients with other conditions revealing the presence of excessive extra skin, especially in the back of the ear. In these patients, modifications need to be made, including resorting to normal classical and long facelift incisions to get rid of the excess skin that has formed.

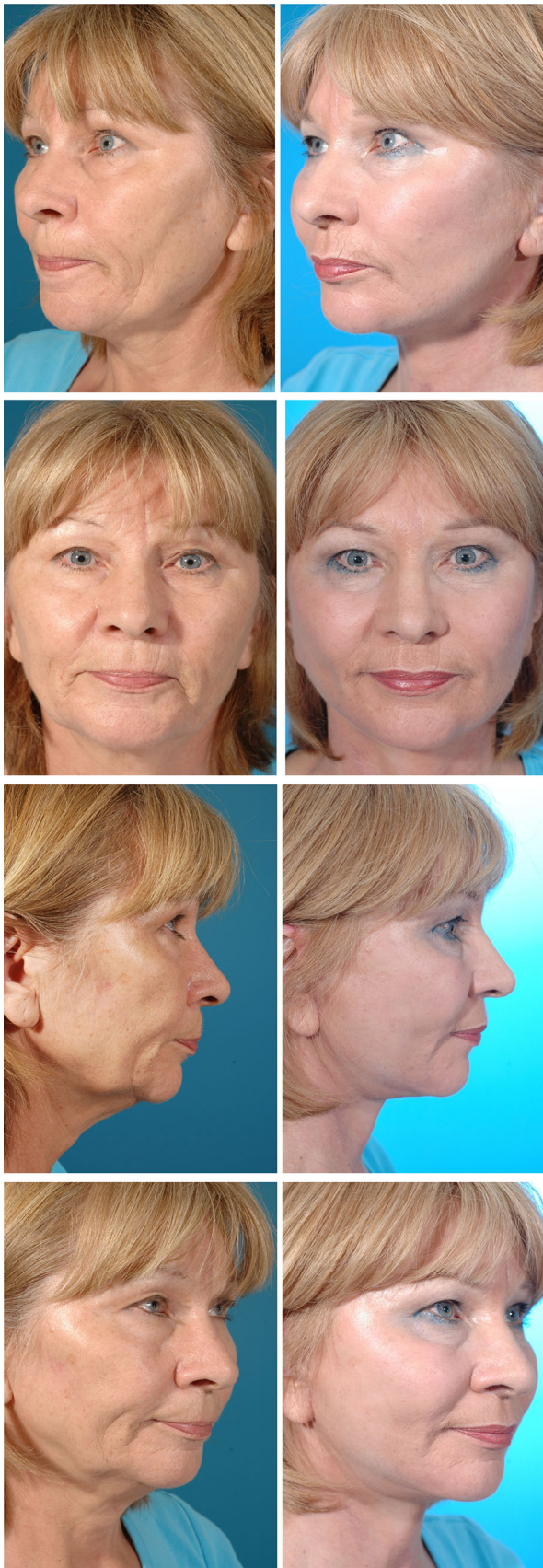All procedures were conducted in compliance with the World Medical Association Declaration of Helsinki Ethical Principles for Medical Research Involving Human Subjects [5].

## Results

### Benefits Observed from the Modified Technique

Of the 612 patients treated using the modified technique beginning in 2005, 441 (72 %) had both ears elevated or prevented from drifting caudally, creating a better post-operative appearance (Figs. 3, 4, 5, 6, 7, 8, 9, 10, and 11). Using 360° round-block, inside-the-ear incisions resulted in a more natural-looking modified facelift. The majority of patients who underwent the novel modified rhytidectomy technique (82 %)—according to a survey conducted by three independent evaluators during follow-up visits 1 year after surgery—reported that they were pleased with their overall results. The average amount of time that the 110 patients presented for follow-up after undergoing this modified rhytidectomy technique was 14 months. We followed these patients much longer (up to 10 years). Additional follow-up involved further changes, such as volume improvements and resurfacing, which caused changes in appearance beyond the scope of this article.

This novel modified rhytidectomy technique is unique and more helpful than the traditional method and other methods of performing rhytidectomy. This technique relies on long subgaleal (subscalp area and the area over the skull) sutures tied under the earlobes, and it relies on placement at the bottom of the ears both back and in a bit higher and more youthful position. Also, this technique prevents the tragus from being pulled forward medially by bringing overrecruited facial skin flap medially to laterally, thus preventing exposure of the ear canal. Finally, this technique involves hiding the incisions as much as possible in the inside tortuosity of the ear and behind it, which assists in getting rid of excess loose skin and hiding the suture line, thereby achieving a natural look without any pulling of the ear and the facial skin. With this technique,



◀**Fig. 3** This 67-year-old woman underwent modified rhytidectomy and forehead endoscopy with upper and lower eyelid blepharoplasty. Nine months after the procedure, the incisions are hidden, and the ears are not deformed and are staying at approximately the same level as they were before the surgery

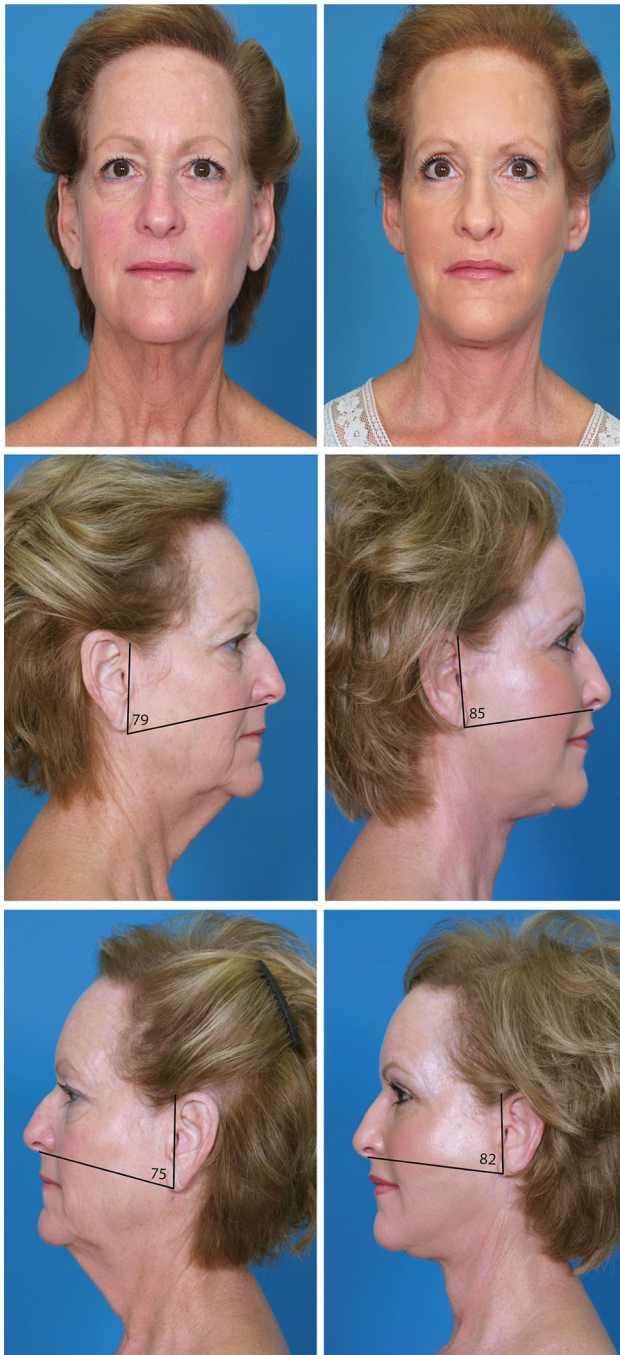
autologous fat injections are used for volume restoration. Restoration of the forehead, eyelids, loose facial tissue, and neck is achieved in the regular manner. This technique prevents and resolves the problem of creating excess skin, which is routinely encountered in many other facelift procedures.

Now there is a new way to ‘measure’ the results of this novel modified rhytidectomy technique. Contrary to many methods that do not address the ear deformity, this modified rhytidectomy technique improves the patient outcome, because it prevents the undesirable effect of drifting caudally. As shown in the modified facelift of many of the patients in Figs. 3, 4, 5, 6, 7, 8, 9, 10, and 11, the angle between the vertical line of the ear and the nose usually changes to become slightly larger than what the patient started with preoperatively. In some cases, the earlobe is shortened to further improve the appearance of youthfulness.

Few postoperative complications occurred in this cohort: four cases of localized small hematomas aspirated during weeks 2 and 3 postoperatively, three cases of short-term muscle imbalance and weakness around the chin resolving in 6 to 8 weeks, and six cases of skin loss (0.5–0.75 cm) were observed. All of these complications healed spontaneously in 2 to 4 weeks without intervention. Most patients in this series returned to activities of daily living within 10 to 14 days after surgery.

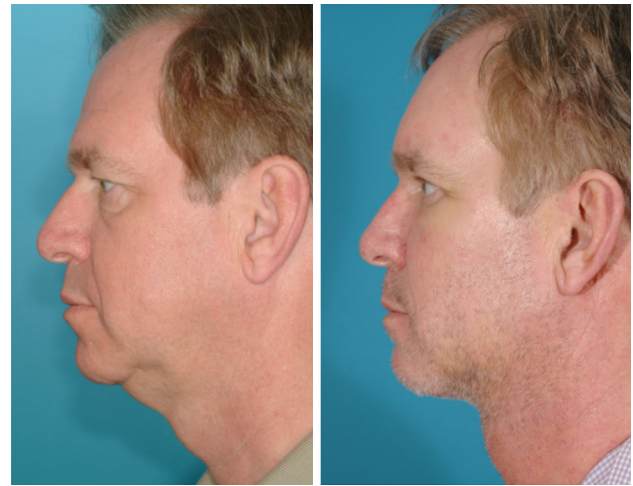This modified rhytidectomy technique compares favorably with both the previously modified technique introduced in 2009 and other existing rhytidectomy techniques. Everyone can tell when a facelift result looks good or bad by looking at it. An objective model to measure the success of a facelift is a measured angle, which helps to indicate and interpret a facelift as attractive or natural looking rather than unattractive or unnatural in appearance. The challenge is how this can be designed, measured, and reported. There is always a fixed angle that is formed between a line from the earlobe and ear canal vertically up the scalp and in between that point and the bottom of the nose. In the so-called pulled look, in which the ear has drifted and pulled caudally, as in pixie ear deformity, that fixed ear-to-nose angle is more acute (smaller) compared with the angle in the preoperative appearance. In the modified facelift, in which the ear does not get pulled so much caudally, that angle is more obtuse (larger) compared





**Fig. 4** This 66-year-old woman underwent modified rhytidectomy and forehead endoscopy with upper and lower eyelid blepharoplasty. Ten months after the procedure, the incisions are hidden and the ears are not deformed. The angle from the right ear to the nose has improved from 79° to 85°, and the angle from the left ear to the nose has improved from 75° to 82°

with the preoperative appearance. We have used this ear-to-nose angle-measurement approach, and found that the angle increased in 72 % of cases of modified facelifts, with the angle becoming more obtuse compared with the preoperative appearance. Therefore, the angle is an objective



**Fig. 5** This 61-year-old man underwent modified rhytidectomy and forehead endoscopy with upper and lower eyelid blepharoplasty. Nine months after the facelift, his face is natural looking and his incisions are hidden without any distortion of the ear

measured number that reflects the natural look that the regular eye can tell even without such a measurement.

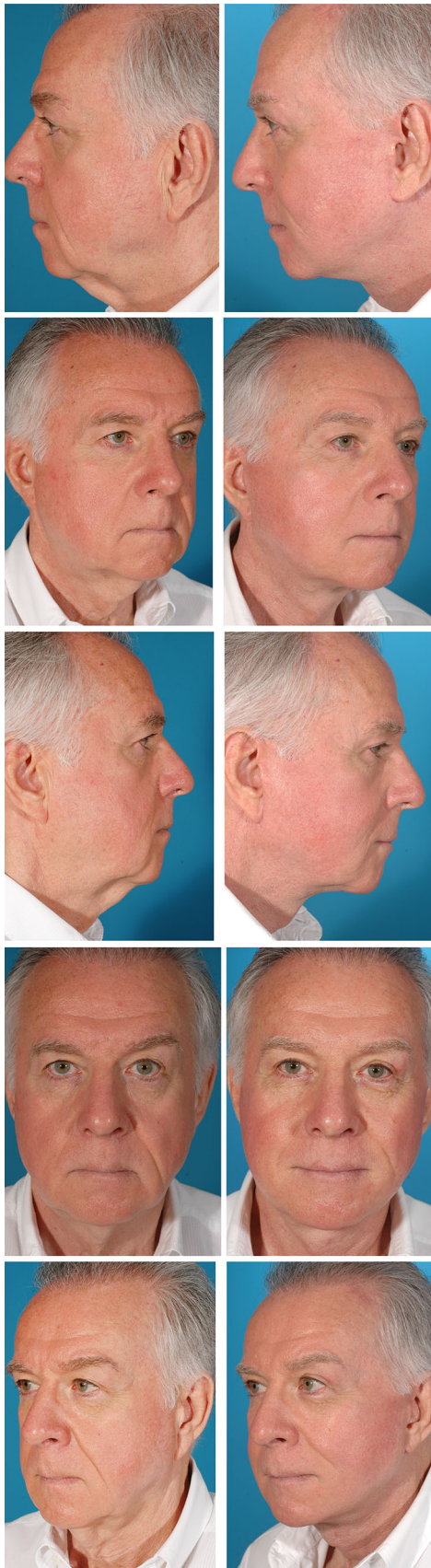After this facelift, it is normal to experience numbness of the skin in front and behind the ear and in the neck area. This temporary phenomenon is related to the cut of sensory nerves during surgery and the lifting of the facial skin that is part of all facelifts. The regeneration of sensory nerves can take from several months to a year to go back to normal. No patient in this series suffered from sensory loss for longer than a few months. It is important to have good knowledge of facial anatomy, especially motor nerves such as the greater auricular nerve, so that the facelift can be carried out safely. The only difference between this modified facelift and others is that an approximately 1 to 1.5 cm incision is made in the superior posterior of the ear, which is not a reason to have a different outcome regarding sensation.

The only place that quill sutures are used is around the ears but not underneath the scalp. The sutures used underneath the scalp are 3-0 absorbable Monocryl sutures. There is no difference in the return of sensation regardless of the kind or suture used.

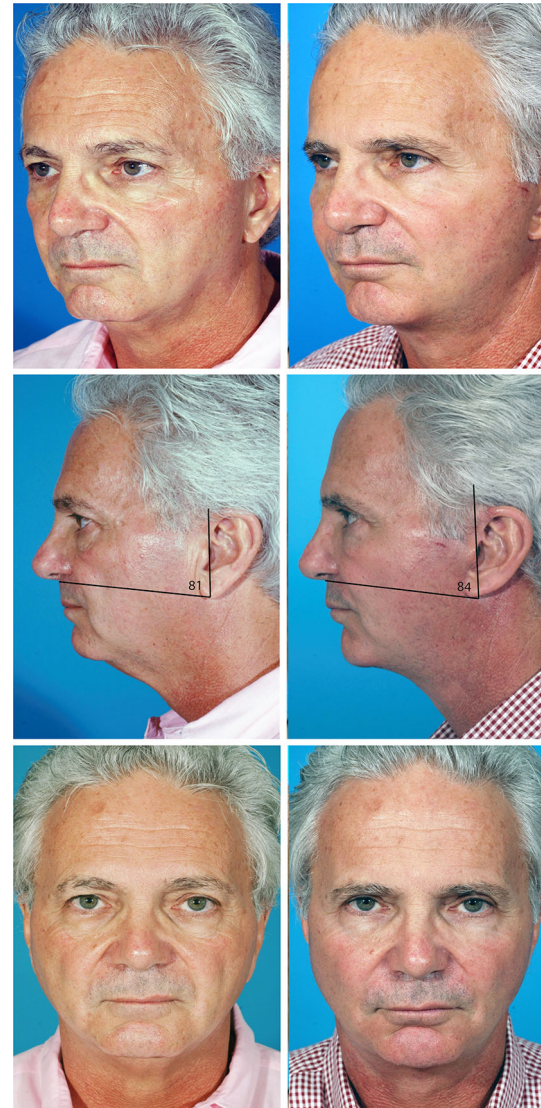## Discussion

The use of 360° round-block, inside-the-ear incisions is advantageous. It is the author's impression that these incisions have much less lymphatic derangement of the skin, because the overall cut is shorter and the skin is not cut as extensively as in other methods that use longer incisions to get rid of more excess skin in facelifts. Other facelift methods also utilize extensive suturing of tissues under tension; thus,





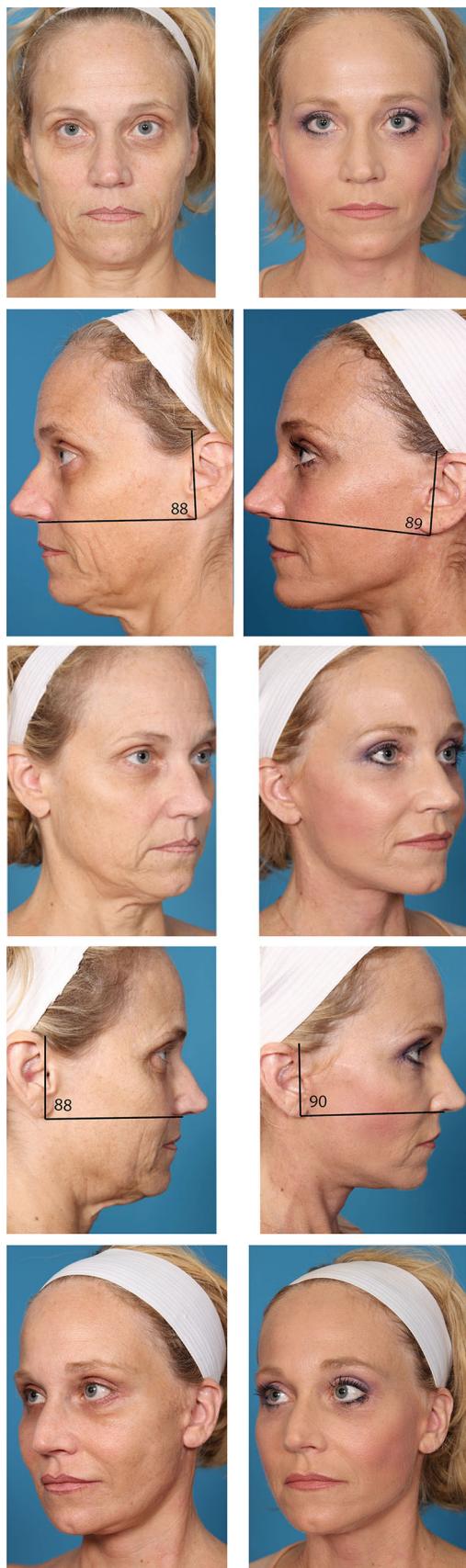◀**Fig. 6** This 71-year-old man underwent modified rhytidectomy and forehead endoscopy with upper and lower eyelid blepharoplasty. Twelve months after the facelift, his face is natural looking and his ears are positioned properly



**Fig. 7** This 68-year-old man underwent modified rhytidectomy and forehead endoscopy with upper and lower eyelid blepharoplasty. Twelve months after the facelift, his face is natural looking. The angle from the left ear to the nose has improved from 81° to 84°

this modified rhytidectomy technique is not unique in that it causes some pain. This more natural-looking modified facelift with few complications is similar to the modified SMAS facelift achieved by Castello et al. [6], who achieved pleasing, natural, durable results with minimal morbidity and a low overall complication rate of just 3.9 %.





◀**Fig. 8** This 50-year-old woman underwent modified rhytidectomy and forehead endoscopy with upper and lower eyelid blepharoplasty. Four months after the facelift, her face is natural looking. The angle from the left ear to the nose has improved from 88° to 89°, and the angle from the right ear to the nose has improved from 88° to 90°

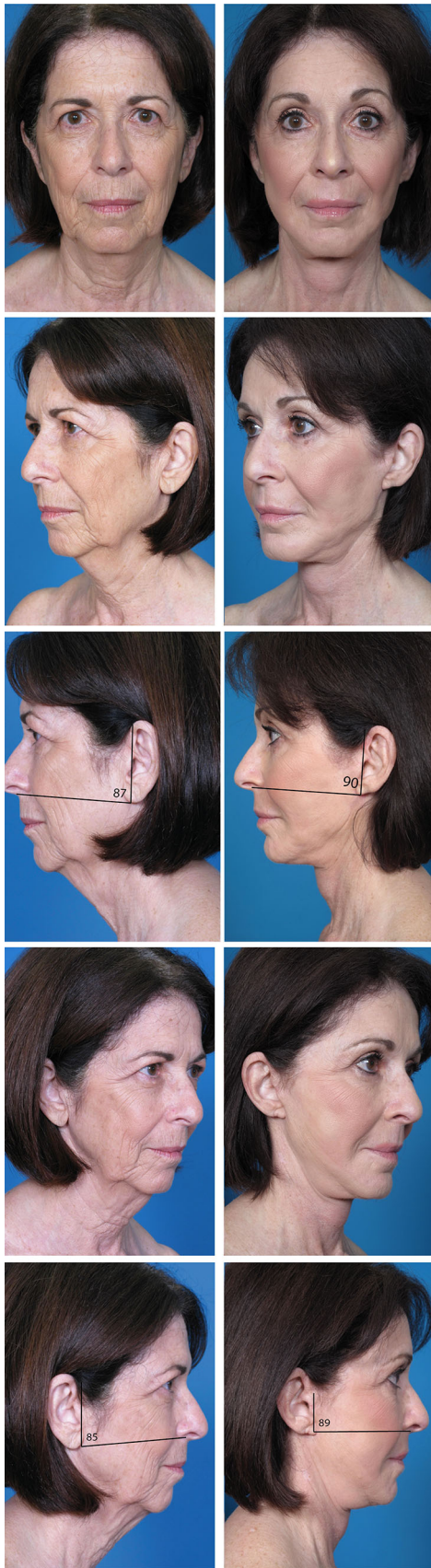There is some concern among surgeons that a short incision in facelift will be a problem partially due to lack of exposure. Although that concern is potentially valid, the size of the incision fortunately appears to be less of an issue than anticipated; as a result, these modified rhytidectomy procedures grew in popularity. Elevation of the facial flap anterior to the ear is performed to the level of the upper zygoma and the superior part of the lower eyelid. Therefore, there should be no limitations to any approach involving the SMAS or platysma repair. None of the 110 cases presented in this article encountered a problem of exposure.

This modified rhytidectomy technique compares very favorably with other techniques of rhytidectomy that claim to prevent earlobe deformity. There is a consensus among the public and surgeons that ear and earlobe deformity is a significant problem. The mere fact that there are numerous local approaches to repair this problem indicates that a very good solution does not exist. There is not a good solution for repairing earlobe deformity, because continuous drifting of the ear and earlobe is greater than most solutions that are offered to repair it. These solutions do not address the real cause and therefore do not come up with a good solution. The problem of drifting caudally with additional scarring recurs frequently [7–10].

Many studies have indicated that facelifts are not pain-free and that pain reduction in these procedures is important [6, 11–19]. The 360° incisions used in this novel modified rhytidectomy technique can possibly contribute to pain. Although the tension on closure of these incisions is a source of pain long term (72 h), local anesthesia such as liposome bupivacaine is used to make the patients much more comfortable without the need to use oral narcotic medications.

Despite the 360° round-block, inside-the-ear incision around the ear, vascularity of the ear is typically not an issue with this modified rhytidectomy technique. With 360° incisions, the blood supply to the skin flap is superior, because there is no cut across the small veins and lymphatics. The blood supply to the external ear is deep, originating from the anterior and posterior auricular arteries. In his extensive experience, this author has not encountered any vascularity issue.

The outer ear is supplied by a number of arteries deeper to the external ear. The posterior auricular artery provides



**Fig. 9** This 66-year-old woman underwent modified rhytidectomy and forehead endoscopy with upper and lower eyelid blepharoplasty, as well as a chin implant. Eleven months after the facelift, the position of her ears has improved. The angle from the left ear to the nose has improved from 87° to 90°, and the angle from the right ear to the nose has improved from 85° to 89°

the majority of the blood supply. The anterior auricular arteries provide some supply to the outer rim of the ear and scalp behind it. The posterior auricular artery is a direct branch of the external carotid artery, and the anterior auricular arteries are branches from the superficial temporal artery. The occipital artery also plays a role.

The incision of 360° around the external ear is very similar to the incisions known for many other facelift procedures. The difference is that instead of curving the incision anterior and posterior to the ear and into the skin, the incision stays within the territory of the external ear. The incision is made very superficial, not deep, and does not cut through the vessels, and most of the external ear skin remains intact, hiding this incision. The new part of the incision is the joining part of the 360° incision between 12 and 1 o'clock. At that part of the ear, there are no feeding blood vessels and there are no blood vessels that need to be cauterized; therefore, there is no greater risk to the ear vascularity similar to that is encountered in many other facelift incisions. The author has not seen any blood supply compromise to the external ears in 15 years of performing this method.

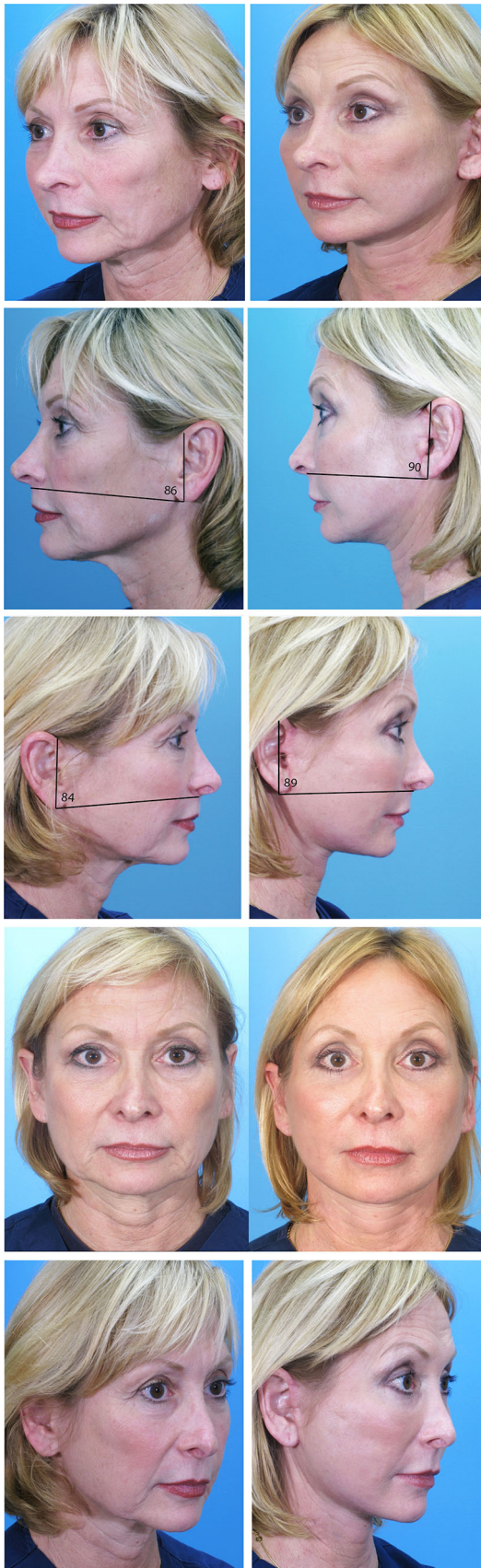This modified rhytidectomy technique has a few weaknesses: there is a learning curve to learning how to perform this procedure, but it is not principally different than that of the common facelift; passing the sutures under the scalp adds approximately 10 min to the procedure and requires a blunt needle; and this procedure is typical of a short scar and therefore is not indicated when there is a lot of excess skin remaining in the neck and face, such as after massive weight loss or when there is extensive extra neck skin.

Thus far, no measurement model has been used to point out the flow of the lymphatic system. It would be beneficial to measure such changes, because intuitively, there is no cut across the postauricular lymphatic system. Therefore, the flow would be superior to one in which there is a cut across and through it, as in classical facelift.

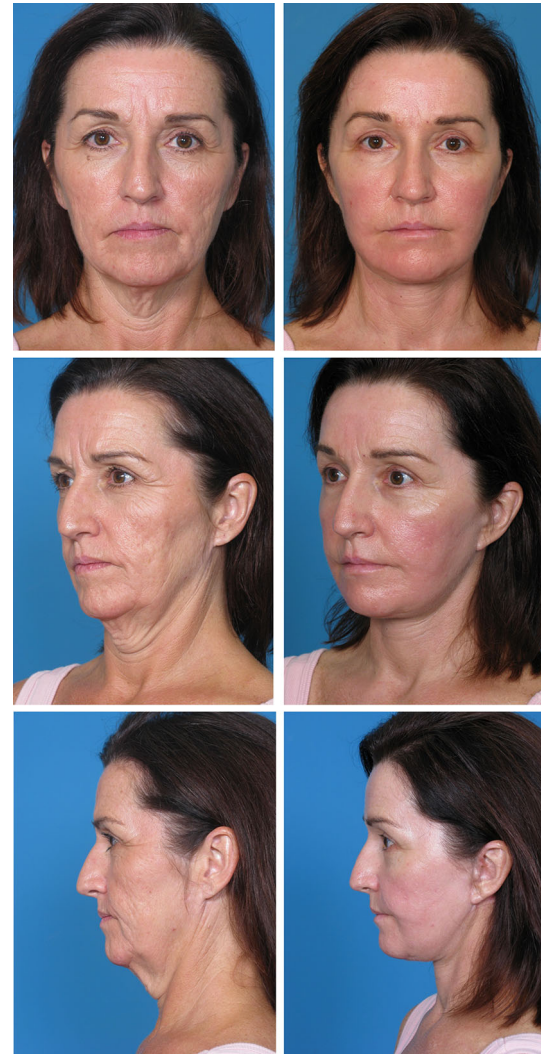## Conclusions

This modified approach to rhytidectomy achieves a more natural looking, aesthetically pleasing result. This is a safe procedure and technically possible to be achieved by any





**Fig. 10** This 57-year-old woman underwent modified rhytidectomy and forehead endoscopy with upper and lower eyelid blepharoplasty. Twelve months after the facelift, the ears position has improved. The angle from the left ear to the nose has improved from  $86^{\circ}$  to  $90^{\circ}$ , and the angle from the right ear to the nose has improved from  $84^{\circ}$  to  $89^{\circ}$



**Fig. 11** This 52-year-old woman underwent modified rhytidectomy and forehead endoscopy with upper and lower eyelid blepharoplasty, as well as a chin implant. Twelve months after the facelift, the ears are at the appropriate level

surgeon who is familiar with most modern facelift techniques.

**Acknowledgments** Dr. Man was involved in the study concept and design, provision of study materials, study supervision, collection and assembly of data, data analysis and interpretation, statistical analysis, manuscript development, and final approval of the manuscript. Edi-

torial assistance was provided by Glenn Floyd, MA. The author was fully responsible for the content, editorial decisions, and opinions expressed in the current article. The author did not receive an honorarium related to the development of this manuscript.

# Compliance with Ethical Standards

**Conflict of interest** The author declares no conflicts of interest with respect to the research, authorship, and publication of this article.

# References

1. Man D (2009) Reducing the incidence of ear deformity in facelift. *Aesthet Surg J* 29(4):264–271
2. Feldman JJ (1990) Corset platysmaplasty. *Plast Reconstr Surg* 85(3):333–343
3. Feldman JJ (1992) Corset platysmaplasty. *Clin Plast Surg* 19(2):369–382
4. Feldman JJ (2014) Neck lift my way: an update. *Plast Reconstr Surg* 134(6):1173–1183
5. World Medical Association. World Medical Association Declaration of Helsinki Ethical Principles for Medical Research Involving Human Subjects. October 2008. <http://www.wma.net/en/30publications/10policies/b3/17c.pdf>. Accessed 1 Mar 2016
6. Castello MF, Lazzeri D, Silvestri A et al (2011) Modified superficial musculoaponeurotic system face-lift: a review of 327 consecutive procedures and a patient satisfaction assessment. *Aesthetic Plast Surg* 35(2):147–155
7. Mowlavi A, Meldrum DG, Wilhelmi BJ (2004) Earlobe morphology delineated by two components: The attached cephalic segment and the free caudal segment. *Plast Reconstr Surg* 113(3):1075–1076
8. Lindgren VV, Carlin GA (1973) Preventing a pulled-down or deformed earlobe in rhytidectomies. *Plast Reconstr Surg* 51(5):598–600
9. Mowlavi A, Meldrum DG, Wilhelmi BJ, Zook EG (2004) Effect of facelift on earlobe ptosis and pseudoptosis. *Plast Reconstr Surg* 114(4):988–991
10. Mowlavi A, Meldrum DG, Wilhelmi BJ et al (2005) The “pixie” ear deformity following facelift surgery revisited. *Plast Reconstr Surg* 115(4):1165–1171
11. Ramanadham SR, Costa CR, Narasimhan K et al (2015) Refining the anesthesia management of the face-lift patient: lessons learned from 1089 consecutive face lifts. *Plast Reconstr Surg* 135(3):723–730
12. Richards BG, Schleicher WF, Zins JE (2014) Putting it all together: recommendations for improving pain management in plastic surgical procedures-surgical facial rejuvenation. *Plast Reconstr Surg* 134(4 Suppl 2):108S–112S
13. Aynehchi BB, Cerrati EW, Rosenberg DB (2014) The efficacy of oral celecoxib for acute postoperative pain in face-lift surgery. *JAMA Facial Plast Surg* 16(5):306–309
14. Taghizadeh F, Ellison T, Traylor-Knowles M (2011) Evaluation of pain associated with facial injections using CoolSkin in rhytidectomy. *J Pain Res* 4:309–313
15. Beer GM, Goldscheider E, Weber A, Lehmann K (2010) Prevention of acute hematoma after face-lifts. *Aesthet Plast Surg* 34(4):502–507
16. Canter HI, Yilmaz B, Gurunluoglu R, Algan H (2006) Use of gabapentin (neurantin) for relief of intractable pain developed after face-lift surgery. *Aesthet Plast Surg* 30(6):709–711
17. Mottura AA (2002) Face lift postoperative recovery. *Aesthet Plast Surg* 26(3):172–180
18. Bailey MH, McKinney P (1988) Herpes zoster as a complication of a face lift. *Aesthet Plast Surg* 12(1):23–24
19. Rees TD, Aston SJ (1978) Complications of rhytidectomy. *Clin Plast Surg* 5(1):109–119